

REVERSE DISTAL SHOE SPACE MAINTAINER – A CASE REPORT WITH 9 MONTHS FOLLOW UP

^[1] Dr. S. Abinaya,^[2] Dr. Joyson Moses,^[3] Dr. Sharanya R,^[4] Dr. Evansal Ranj J

^[1] Post Graduate , Department of Pediatric and Preventive Dentistry, Thai Moogambigai Dental College and Hospital, Chennai ,India.

Head of the Department , Pediatric and Preventive Dentistry, Thai Moogambigai Dental College and Hospital, Chennai ,India.

Reader , Department of Pediatric and Preventive Dentistry, Thai Moogambigai Dental College and Hospital, Chennai ,India.

Post Graduate , Department of Pediatric and Preventive Dentistry, Thai Moogambigai Dental College and Hospital, Chennai ,India.


To access & cite this article

Website: tmjpbs.com



ABSTRACT

A 9 year old girl reported with Pre shedding mobility in 84 85. The treatment included the extraction of 84 85 followed by the placement of a Reverse Distal Shoe Space Maintainer for guiding the eruption of the right second premolar in position. 9 months follow up was done which revealed the proper eruption position of the second premolar.



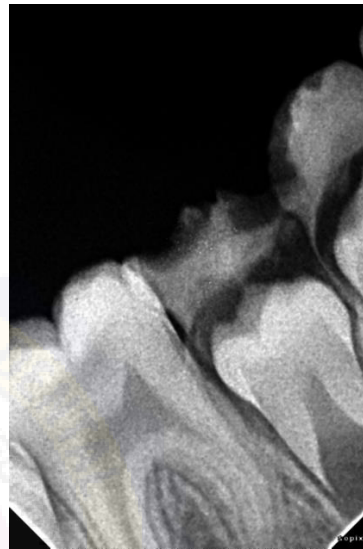
INTRODUCTION

For a pedodontists it is of great significance to maintain the primary teeth in their positions till the permanent teeth erupt. Nevertheless they may be extracted in some children if there is extensive or rapid caries. Monitoring the shedding of the baby teeth and the eruption of adult (permanent) teeth, called the "mixed dentition phase,"(1) In particular the loss of the primary molars will lead to malocclusion. There could be the reduction of the arch length if there is a loss of the primary teeth prematurely. This may lead to the improper guidance to the erupting permanent molars and the premolars. To overcome this, the space maintainers are used. Various space maintainers can be given to the children, subject to the cooperation, age, missing teeth, patient's dental arch, stage of dental development, and dentition .(2) Retention of a nonvital second primary molar before and during the eruption of the permanent first molar has been advocated for a long time. If, however, the second primary molar is extracted, severe space loss probably would occur (Forrester et al. 1981; Stewart et al. 1982; Goerig and Camp 1983; Mathewson et al. 1987; McDonald and Avery 1987; Pinkham 1988). Even when the prognosis is in doubt, root canal treatment of the infected primary second molar allows the first permanent molar to erupt fully into its normal position after which the second molar can be removed and an appropriate space management technique initiated. (3) One of the various types of fixed space maintainer is called a distal shoe appliance. The back portion is inserted under the gums. It is used when a child loses the baby tooth in front of a 6-year molar that has not yet come into the mouth.(4)This case report presents a reverse distal shoe space maintainer placement with a 9 months follow up.

Case Report

A 9 year old girl visited the Department of Pedodontics and Preventive Dentistry , Thai Moogambigai Dental College and Hospital with a chief complaint of shaking of lower right side back teeth for the past 1 month. There were no relevant medical history and Past Dental history. Intra Oral Examination revealed the presence of mixed dentition stage . Preshedding mobility in 84 , 85 and Class I dental caries in 46 and 36. Radiological examination revealed the presence of resorption in 84 and 85 with erupting succedaneous teeth. The treatment of choice was extraction of 84 85 under local anesthesia followed by the placement of a

reverse Distal Shoe Space Maintainer for guiding the eruption of the second premolar.



. Fig 1: Preoperative Radiograph

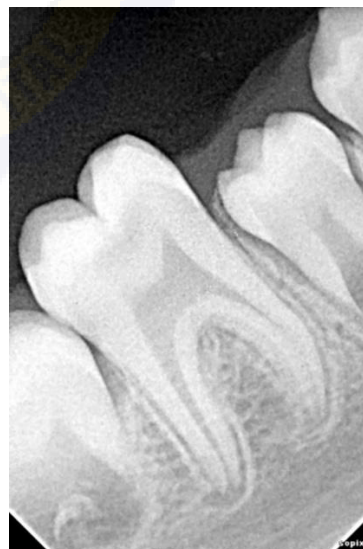

Fig 2: Post Extraction Radiograph

PROCEDURE

The procedure was carried out in two appointments. In the first appointment extraction of 84 and 85 was done under local anesthesia followed by prescribing systemic analgesics and antibiotics. In the second appointment , A band was fabricated in the adjacent tooth 46 and alginate impression was taken. Model analysis was done by using the radiographs.

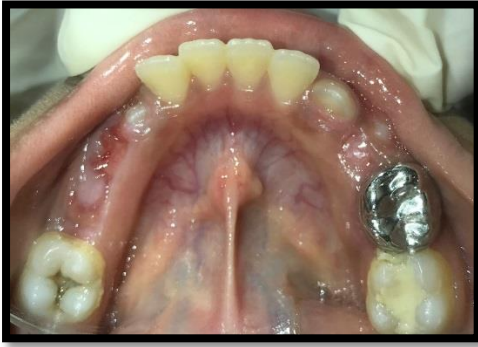

Fig 3 : Post Extraction Photograph

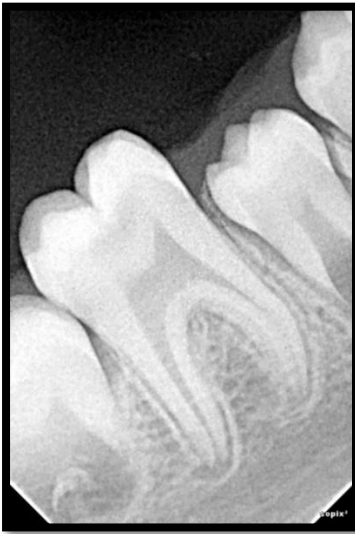

Fig 4 : Post Extraction Radiograph

Fabrication

The mesiodistal diameter of the Erupting premolar was measured . The distal extension was made accordingly and a bend was given 1mm below into the soft tissues. A radiographic confirmation was done to check the position of the bend in relation to the erupting tooth. The band and the distal extension were soldered , polished and cemented onto the tooth. The parents were explained about the follow ups and the oral hygiene instructions.

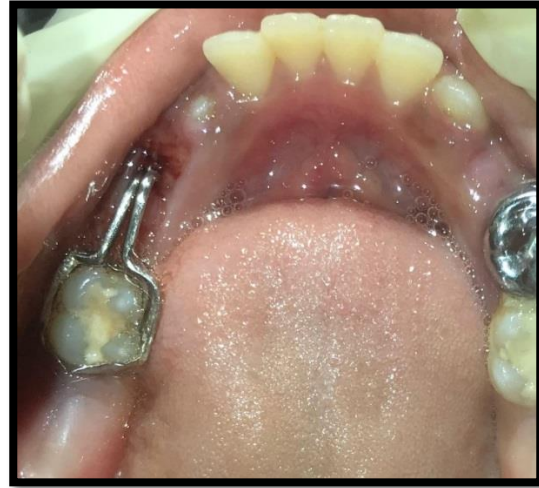

Fig 5 : Reverse Distal Shoe Space Maintainer cementation

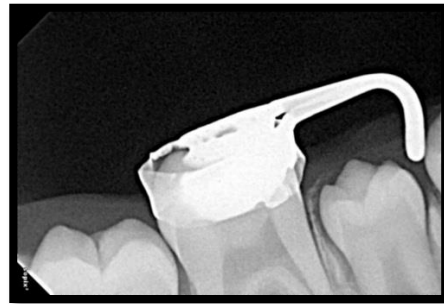


Figure 6 : Radiograph revealing the Depth

Patient reported after 9 months. The radiographic interpretation revealed the eruption of second premolar at its proper position. After confirming with the radiograph , the space maintainer was removed.

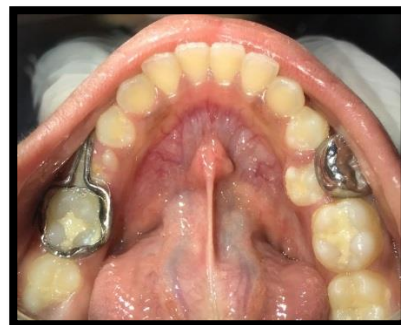

Figure 7 : 9 months follow up

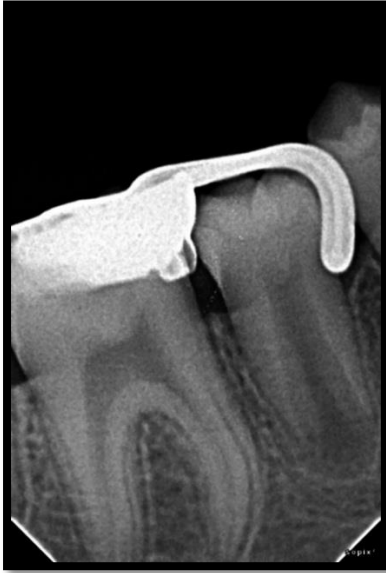

Figure 8 : Radiograph revealing the eruption of second premolar

Discussion

Dental caries is one of the most common reason for the premature loss of primary teeth.(5) Premature loss of a primary second molar may lead to space loss in the dental arch. This space loss tends to be more severe in unfavourable malocclusions. Loss of arch-length has been related mainly with tooth migration following premature loss of primary teeth. It is considered one of the most frequent aetiology for space loss in children. Loss of arch-length results in a loss of structural balance and functional efficiency. Space management includes space maintenance, space regaining, space supervision and serial extraction.(6) A space maintainer (SM) is a fixed or removable device used to maintain the length of the arch after the loss or premature extraction of a primary teeth (due to trauma, damage, or other factors).The removable space maintainer can maintain the toothless space, restore masticatory function and aesthetics. However, the removable Space maintainer has some drawbacks such as poor retention, poor child tolerance, and a high probability of the tool getting loose. Meanwhile, the use of a fixed space maintainer would be more suitable for longer maintenance periods. The use of fixed space

maintainers is well tolerated and durable. The fixed space maintainer should be removed once a year to allow examination, cleaning, and application of fluoride to the teeth(7) The distal shoe space maintainer, as introduced by Gerber and extended by Croll. is a valuable part of the pediatric dentist's armamentarium, because in those cases where the second primary molar is lost prematurely, it helps guide the first permanent molar into place.(8)The distal shoe space maintainer (DSSM) may be beneficial in controlling the path of eruption of an unerupted permanent first molar from the primary into the early mixed dentition.(9) The choice of the space maintainer depends on the condition of the patient, the experience of the pedodontists also plays an important role. The choice depends on the first permanent molar position if that has erupted or not. The conditions that will preclude the use of the conventional distal shoe are premature loss of multiple primary molars. In such conditions the modified distal shoe can be used(2) There are different types of space maintainer according to indication and design . Distal shoe space maintainers are indicated to guide the unerupted or erupting permanent first molar into normal eruptive position followed by premature loss of primary second molar . This is a type of intra alveolar appliance where distal extension bar is positioned inside the alveolus contacting the mesial surface of erupting permanent first molar . Conventional design of distal shoe space maintainer was not advocated in the present case due to multiple loss of lower primary molars. According to the case report given by Prasanna Kumar Bhat et al he stated that the Stability of the appliance would have been a major issue in that case, if they had given distal shoe space maintainer by banding canine. So the design of distal shoe was modified such that it is able to maintain mesiodistal dimension of the space without any compromise on the stability or cooperation of the patient (10) .Case selection is very important because distal shoe space maintainers are generally not preferred because it needs surgical

intervention and it is not hygienic also the compliance is very poor. In the present case report, modification of distal shoe space maintainer has been used. Reverse distal shoe space maintainer was the treatment option put forward. The patient had a necessity of extraction of primary canine and both primary molars. For the guidance of eruption of premolar this modification was given. The appliance had this own disadvantages like the discomfort , improper oral maintenance. The parent and the child was given oral hygiene instructions and on how to maintain the space maintainer. Follow up appointment's were scheduled accordingly. After 9 months of follow up , there was proper guidance of eruption of the permanent premolar, satisfactory results were obtained.

Conclusion

Modifications of distal shoe has been widely used. Different modifications are being invented for the proper guidance for the eruption of the permanent teeth. Each of its own has its own advantages and disadvantages. The treatment option and the modification should be determined by the operator depending on the diagnosis and prognosis.

REFERENCES:

1. Types of Space Maintainers for Children. 2020 [cited 2022 Mar 30].
2. reverse distal shoe space maintainer
3. Gellin ME, Spedding DRH. Space management required after unsuccessful root canal therapy of a mandibular second primary molar: case report. :4.
4. Space Maintainers in Oak Harbor & Anacortes, WA [Internet]. Playhouse Dental. [cited 2022 Mar 30].
5. Nayak UA, Loius J, Sajeev R, Peter J. Band and loop space maintainer--made easy. J Indian Soc Pedod Prev Dent. 2004 Sep;22(3):134–6.
6. Wilson B, Joseph J, Bharadwaj P, Chand K. Space Management in Paediatric Dentistry. Journal of Dental Panacea. 2014 Jan 13;1:1.
7. Achmad H. The Use of Space Maintainer in Pediatric Dentistry: A Systematic Review. Clinical Medicine. 2021;08(02):14.
8. Bhat PK. Modified Distal Shoe Appliance for Premature Loss of Multiple Deciduous Molars: A Case Report. JCDR [Internet]. 2014 [cited 2022 Mar 30];
9. Nouri MR, Kennedy DB. Optimal fit of chairside-fabricated distal shoe space maintainer. Eur Arch Paediatr Dent. 2013 Oct;14(5):351–4.
10. Bhat PK, K. NH, Idris M, Christopher P, Rai N. Modified Distal Shoe Appliance for Premature Loss of Multiple Deciduous Molars: A Case Report. J Clin Diagn Res. 2014 Aug;8(8):ZD43–5.